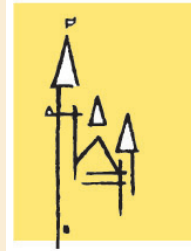


STAD AALST



DENDEREND



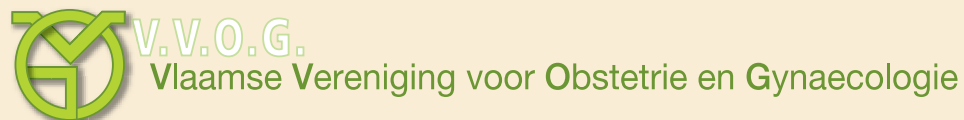**SOCIÉTÉ BELGE DE CYTOLOGIE CLINIQUE  
BELGISCHE VERENIGING VOOR KLINISCHE CYTOLOGIE**

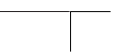
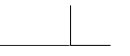# **Belgian Follow-up Expert Guidelines for Cervical Cytology Abnormal cervical smears**

**Edited with the participation of**

**Belgische Vereniging voor Klinische Cytologie - Société Belge de Cytologie Clinique  
Vlaamse Vereniging voor Obstetrie en Gynaecologie  
Groupement des Gynécologues Obstétriciens de Langue Française de Belgique**

**Presented at the 2004 Spring Meeting of the BVKC/SBCC, Aalst, June 19th 2004**





**Note:**

*- These guidelines are intended as an addition to the follow-up guidelines published in 1996. For items whose follow-up schemes are unchanged (normal smears whether or not of sufficient quality, smears with endometrial cells present), we refer to this previous version.*

*- Terminology used is based on TBS2001.*

*- The terms atypical squamous cells (ASC) and atypical endocervical cells (AGC-ec) refer to cytologic changes suggestive of SIL (ASC-US > LSIL; ASC-H > HSIL) and endocervical AIS respectively, which are qualitatively or quantitatively insufficient for a definitive interpretation. Consequently, a neoplastic lesion may not be present. The demonstration of HPV in these cases corroborates the plausibility of a neoplastic lesion.*

*- If conventional smears (and not LBC) are used, concurrent HPV-testing is not always possible. In that case, HPV-testing is performed in a second time.*

*- Several methods for detection of HPV exist. Solution hybridisation with Hybrid Capture II (HCII, Digene Inc) as well as PCR with the MY09/MY11 and GP5+/GP6+ primer sets were tested and validated on both Thinprep (Cytyc Inc) and Surepath (Tripath Inc) samples.*

*- If Digene HCII is used, testing for LR-HPV is only performed when HR-HPV (oncogenic HPV) is borderline positive.*

*- Integrated reporting of cytology and HPV-testing is recommended. (e.g.: results: HR-HPV positive ASC-US; interpretation: most consistent with LSIL).*

## Atypical squamous cells of undetermined significance (ASC-US)

### ASC-US in a woman > 25y

**or** concurrent HPV-test (preferred):

- HR positive            ➡ colposcopy + biopsy within 3m
- LR positive           ➡ repeat smear after 6m:
  - positive            ➡ colposcopy + biopsy
  - negative           ➡ normal interval
- HPV negative        ➡ repeat smear after 12m:
  - positive           ➡ colposcopy + biopsy
  - negative           ➡ normal interval

**or** repeat smear after 6m:

- positive            ➡ colposcopy + biopsy
- negative           ➡ repeat smear after 12m +/- HPV-test:
  - both negative        ➡ normal interval
  - one or both positive ➡ colposcopy + biopsy

**or** colposcopy + biopsy:

- positive            ➡ treatment according to lesion
- negative           ➡ repeat smear after 12m +/- HPV-test:
  - both negative        ➡ normal interval
  - one or both positive ➡ colposcopy + biopsy

## ASC-US in a woman < 25y

(different policy because of high rate of spontaneous regression)

### **or** concurrent HPV-test (preferred):

- HR positive
  - ➔ repeat smear after 6m:
    - positive ➔ colposcopy + biopsy
    - negative ➔ concurrent HPV-test
      - positive ➔ colposcopy + biopsy
      - negative ➔ repeat smear after 12m +/- HPV-test:
        - both negative ➔ normal interval
        - one or both positive ➔ colposcopy+ biopsy
- LR positive
  - ➔ repeat smear after 6m:
    - positive ➔ colposcopy + biopsy
    - negative ➔ normal interval
- HPV negative
  - ➔ repeat smear after 12m:
    - positive ➔ colposcopy + biopsy
    - negative ➔ normal interval

### **or** repeat smear after 6m:

- positive ➔ colposcopy + biopsy
- negative ➔ repeat smear after 12m +/- HPV-test:
  - both negative ➔ normal interval
  - one or both positive ➔ colposcopy + biopsy

### **or** colposcopy + biopsy (if persistent lesion):

- positive ➔ treatment according to lesion
- negative ➔ repeat smear after 12m +/- HPV-test:
  - both negative ➔ normal interval
  - one or both positive ➔ colposcopy + biopsy

## ASC-US in a post-menopausal woman

**or** concurrent HPV-test (preferred):

- HR positive            ➡ colposcopy + biopsy within 3m
- LR positive           ➡ repeat smear after 6m:
  - positive           ➡ colposcopy + biopsy
  - negative           ➡ normal interval
- HPV negative         ➡ repeat smear after 12m:
  - positive           ➡ colposcopy + biopsy
  - negative           ➡ normal interval

**or** estrogen intravaginal ➡ repeat smear 1-2w after therapy:  
(if no contra-indications and atrophy present)

- positive           ➡ concurrent HPV-test (preferred)
  - ➡ colposcopy + biopsy
- negative           ➡ repeat smear after 6m:
  - negative           ➡ normal interval

**or** colposcopy + biopsy:

- positive           ➡ treatment according to lesion
- negative           ➡ repeat smear after 12m +/- HPV-test:
  - both negative           ➡ normal interval
  - one or both positive   ➡ colposcopy + biopsy

## Low grade squamous intra-epithelial lesion (LSIL)

(cfr ASC-US, but without preference)

### LSIL in a woman > 25y

#### **or** concurrent HPV-test:

- |              |   |
|--------------|---|
| HR positive  | ➔ colposcopy + biopsy within 3m   |
| LR positive  | ➔ repeat smear after 6m:<br>positive ➔ colposcopy + biopsy<br>negative ➔ normal interval  |
| HPV negative | ➔ repeat smear after 12m:<br>positive ➔ colposcopy + biopsy<br>negative ➔ normal interval |

#### **or** repeat smear after 6m:

- |          |   |
|----------|---|
| positive | ➔ colposcopy + biopsy   |
| negative | ➔ repeat smear after 12m +/- HPV-test:<br>both negative ➔ normal interval<br>one or both positive ➔ colposcopy + biopsy |

#### **or** colposcopy + biopsy:

- |          |   |
|----------|---|
| positive | ➔ treatment according to lesion   |
| negative | ➔ repeat smear after 12m +/- HPV-test:<br>both negative ➔ normal interval<br>one or both positive ➔ colposcopy + biopsy |

## LSIL in a woman < 25y

(different policy because of high rate of spontaneous regression)

### **or** concurrent HPV-test:

- HR positive
  - ➡ repeat smear after 6m:
    - positive ➡ colposcopy + biopsy
    - negative ➡ concurrent HPV-test
      - positive ➡ colposcopy + biopsy
      - negative ➡ repeat smear after 12m +/- HPV-test:
        - both negative ➡ normal interval
        - one or both positive ➡ colp. + biopsy
- LR positive
  - ➡ repeat smear after 6m:
    - positive ➡ colposcopy + biopsy
    - negative ➡ normal interval
- HPV negative
  - ➡ repeat smear after 12m:
    - positive ➡ colposcopy + biopsy
    - negative ➡ normal interval

### **or** repeat smear after 6m:

- positive ➡ colposcopy + biopsy
- negative ➡ repeat smear after 12m +/- HPV-test:
  - both negative ➡ normal interval
  - one or both positive ➡ colposcopy + biopsy

### **or** colposcopy + biopsy (if persistent lesion):

- positive ➡ treatment according to lesion
- negative ➡ repeat smear after 12m +/- HPV-test:
  - both negative ➡ normal interval
  - one or both positive ➡ colposcopy + biopsy

## **LSIL in a post-menopausal woman**

### **or** concurrent HPV-test:

- HR positive            ➡ colposcopy + biopsy within 3m
- LR positive           ➡ repeat smear after 6m:
  - positive           ➡ colposcopy + biopsy
  - negative          ➡ normal interval
- HPV negative        ➡ repeat smear after 12m:
  - positive          ➡ colposcopy + biopsy
  - negative          ➡ normal interval

### **or** estrogen intravaginal > repeat smear 1-2w after therapy: (if no contra-indications and atrophy present)

- positive            ➡ concurrent HPV-test (preferred)
  - ➡ colposcopy + biopsy
- negative           ➡ repeat smear after 6m:
  - negative          ➡ normal interval

### **or** colposcopy + biopsy:

- positive           ➡ treatment according to lesion
- negative           ➡ repeat smear after 12m +/- HPV-test:
  - both negative      ➡ normal interval
  - one or both positive ➡ colposcopy + biopsy

## **Atypical squamous cells, cannot exclude HSIL (ASC-H)**

➡ colposcopy + biopsy (*preferably following HPV-test*) :

positive      ➡ treatment according to lesion

negative      ➡ re-evaluation cytology / histology / colposcopy

    probably HSIL      ➡ diagnostic excision

    probably not HSIL      ➡ repeat smear after 3-6m +/- HPV-test:

        both negative      ➡ normal interval

        one or both positive      ➡ colposcopy + biopsy

## High grade squamous intra-epithelial lesion (HSIL)

➔ colposcopy + biopsy:

positive ➔ treatment according to lesion

negative ➔ re-evaluation cytology / histology / colposcopy

probably HSIL ➔ diagnostic excision

probably not HSIL ➔ repeat smear after 3-6m +/- HPV-test:

both negative ➔ normal interval

one or both positive ➔ colposcopy + biopsy

*(if desired: HPV-typing (not testing))*

## **Atypical endocervical cells (AGC-ecc), NOS**

### **or** concurrent HPV-test:

- HR positive            ➡ colposcopy + biopsy within 3m
- LR positive           ➡ repeat smear after 6m:
  - positive           ➡ colposcopy + biopsy
  - negative           ➡ normal interval
- HPV negative        ➡ repeat smear after 12m:
  - positive           ➡ colposcopy + biopsy
  - negative           ➡ normal interval

### **or** repeat smear after 3-6m +/- HPV-test:

- one or both positive ➡ colposcopy + biopsy
- both negative       ➡ repeat smear after 12m +/- HPV-test:
  - both negative       ➡ normal interval
  - one or both positive ➡ colposcopy + biopsy

### **or** colposcopy + biopsy:

- positive           ➡ treatment according to lesion
- negative           ➡ repeat smear after 12m +/- HPV-test:
  - both negative       ➡ normal interval
  - one or both positive ➡ colposcopy + biopsy

## **Atypical endocervical cells (AGC-ecc), favor neoplastic**

➔ colposcopy + biopsy (endocervical sampling) (preferably following HPV-test):

positive ➔ treatment according to lesion

negative ➔ re-evaluation cytology / histology / colposcopy  
probably AIS ➔ diagnostic excision  
probably not AIS ➔ repeat smear after 3-6m +/- HPV-test:  
both negative ➔ normal interval  
one or both positive ➔ colposcopy + biopsy

## Endocervical adenocarcinoma in situ (AIS)

➔ colposcopy + biopsy (endocervical sampling)

positive ➔ treatment according to lesion

negative ➔ re-evaluation cytology / histology / colposcopy

probably AIS ➔ diagnostic excision

probably not AIS ➔ repeat smear after 3-6m +/- HPV-test:

both negative ➔ normal interval

one or both positive ➔ colposcopy + biopsy

*(if desired: HPV-typing (not testing))*

## **Normal smear after treatment for HSIL or AIS-ecc**

➔ HPV-test 6m after treatment + repeat smear:

one or both positive ➔ colposcopy +biopsy

both negative ➔ repeat smear + HPV-test after 6m  
both negative ➔ normal interval

*(HPV-test is performed not sooner than 6m after treatment to avoid false positives)*

## Literature

Agence Nationale d'Accréditation et d'Évaluation en Santé (ANAES) -Service des recommandations professionnelles  
- Service évaluation économique : Conduite à tenir devant une patiente ayant un frottis cervico-utérin anormal.  
Actualisation 2002

ALTS-Group. Human papillomavirus testing for triage of women with cytologic evidence of low-grade squamous intraepithelial lesions: baseline data from a randomized trial. *J Natl Cancer Inst* 2000; **92**: 397-402.

ALTS-Group. Results of a randomised trial on the management of cytology interpretations of atypical squamous cells of undetermined significance. *Am J Obstet Gynecol* 2003;188: 1383-92

Bergeron C, Jeannel D, Poveda J et al: HPV testing in women with mild cytologic atypia. *Obstet Gynecol* 2000; **95**: 821-7

Bosch FX, Manos MM, Munoz N, Sherman M, Jansen AM, Peto J, Schiffman MH, Moreno V, Kurman R, Shah KV. Prevalence of human papillomavirus in cervical cancer: a worldwide perspective. International biological study on cervical cancer (IBSCC) Study Group. *J Natl Cancer Inst* 1995; **87**: 796-802.

Castellsague X, Menendez C, Loscertales MP, Kornegay JR, dos Santos F, Gomez-Olive FX, Lloveras B, Abarca N, Vaz N, Barreto A, Bosch FX, Alonso P. Human papillomavirus genotypes in rural Mozambique. *Lancet* 2001; **358**: 1429-30.

Chichareon S, Herrero R, Munoz N, Bosch FX, Jacobs MV, Deacon J, Santamaria M, Chongsuvivatwong V, Meijer CJ, Walboomers JM. Risk factors for cervical cancer in Thailand: a case-control study. *J Natl Cancer Inst* 1998; **90**: 50-7.

Depuydt CE, Vereecken AJ, Salembier GM, Vanbrabant AS, Boels LA, Van Herck E, Arbyn M, Segers K, Bogers JJ. Thin-layer liquid-based cervical cytology and PCR for detecting and typing human papillomavirus DNA in Flemish women. *Br J Cancer* 2003; **88**: 560-6.

Eluf-Neto J, Booth M, Munoz N, Bosch FX, Meijer CJ, Walboomers JM. Human papillomavirus and invasive cervical cancer in Brazil. *Br J Cancer* 1994; **69**: 114-9.

Herrero R, Hildesheim A, Bratti C, Sherman ME, Hutchinson M, Morales J, Balmaceda I, Greenberg MD, Alfaro M, Burk RD, Wacholder S, Plummer M, Schiffman M. Population-based study of human papillomavirus infection and cervical neoplasia in rural Costa Rica. *J Natl Cancer Inst* 2000; **92**: 464-74.

Lazcano-Ponce E, Herrero R, Munoz N, Cruz A, Shah KV, Alonso P, Hernandez P, Salmeron J, Hernandez M. Epidemiology of HPV infection among Mexican women with normal cervical cytology. *Int J Cancer* 2001; **91**: 412-20.

Manos MM, Kinney WK, Hurley LB et al: Identifying women with cervical neoplasia: using HPV DNA testing for equivocal Papanicolaou results. *JAMA* 1999; **281**: 1605-10

Munoz N, Bosch FX, de Sanjose S, Herrero R, Castellsague X, Shah KV, Snijders PJ, Meijer CJ. Epidemiologic classification of human papillomavirus types associated with cervical cancer. *N Engl J Med* 2003; **348**: 518-27.

Ngelangel C, Munoz N, Bosch FX, Limson GM, Festin MR, Deacon J, Jacobs MV, Santamaria M, Meijer CJ, Walboomers JM. Causes of cervical cancer in the Philippines: a case-control study. *J Natl Cancer Inst* 1998; **90**: 43-9.

Partridge EE. NCCN practice guidelines for cervical cancer screening. Version 2, 2003 [www.nccn.org/professionals/physician\\_gls/f\\_guidelines.asp#detection](http://www.nccn.org/professionals/physician_gls/f_guidelines.asp#detection)

Rolon PA, Smith JS, Munoz N, Klug SJ, Herrero R, Bosch X, Llamas F, Meijer CJ, Walboomers JM. Human papillomavirus infection and invasive cervical cancer in Paraguay. *Int J Cancer* 2000; **85**: 486-91.

Santos C, Munoz N, Klug S, Almonte M, Guerrero I, Alvarez M, Velarde C, Galdos O, Castillo M, Walboomers J, Meijer C, Caceres E. HPV types and cofactors causing cervical cancer in Peru. *Br J Cancer* 2001; **85**: 966-71.

Saslow D, Runowicz CD, Solomon D et al: American Cancer Society guideline for the early detection of cervical neoplasia and cancer. *CA Cancer J Clin* 2002; **52**: 342-362

Schiffman M, Adriaenza ME. ASCUS-LSIL Triage Study. Design, methods and characteristics of trial participants. *Acta Cytol* 2000; **44**: 726-42.

Solomon D, Nayar R: The Bethesda System for reporting cervical cytology: definitions, criteria and explanatory notes. 2nd ed, Springer, 2004

Solomon D, Schiffman M, Tarone R. Comparison of three management strategies for patients with atypical squamous cells of undetermined significance: baseline results from a randomized trial. *J Natl Cancer Inst* 2001; **93**: 293-9.

Wright TC Jr, Cox JT, Massad LS, Twiggs LB, Wilkinson EJ. ASCCP-sponsored Consensus Conference. 2001 Consensus Guidelines for the management of women with cervical cytological abnormalities. *JAMA* 2002; **287**: 2120-9.

Zielinski DG, Snijders PJ, Rozendaal L, Voorhorst FJ, Runsink AP, de Schipper FA, Meijer CJ. High-risk HPV testing in women with borderline and mild dyskaryosis: long-term follow-up data and clinical relevance. *J Pathol* 2001; **195**: 300-6.

## **Participants**

### **Belgische Vereniging voor Klinische Cytologie - Société Belge de Cytologie Clinique**

- *M. Drijkoningen (president)*
- *B. Weynand (vice-president)*
- *C. Bourgain (secretary nl)*
- *Ph. Delvenne (secretary fr)*
- *L. Thienpont (treasurer)*
- *JP. Bogers*
- *C. Cuvelier*
- *M. Kevers*
- *M-A. Reginster*
- *M. Rimmelinck*
- *A. Verhest*
- *F. Willocx*

### **Vlaamse Vereniging voor Obstetrie en Gynaecologie (VVOG) Vlaamse Werkgroep Oncologische Gynaecologie (VWOG)**

#### **- Bestuur VVOG**

- *G. Debruyne (voorzitter)*
- *J. Gerris (ondervoorzitter)*
- *C. Derop (eerste secretaris)*
- *F. De Prins (penningmester)*
- *J. Van Wiemeersch (woordvoerder)*
- *L. De Baene (interne communicatie)*
- *W. Ombelet (wetenschappelijke raad)*
- *P. Defoort (SPE)*
- *P. Koninckx (internationale contacten)*
- *C. Blockeel (vertegenwoordiger aspiranten-leden)*
- *M. Parisis (administratief secretaris)*

#### **- Commissie voor Colposcopie en cervixpathologie**

- *W. Poppe (voorzitter)*
- *Ph. De Sutter (secretaris)*
- *P. Cryns*
- *P. Ide*
- *G. Orye*
- *W. Tjalma*
- *J. Verguts*
- *K. Watty*
- *S. Weyers*
- *K. Wuyts*

## **Groupement des Gynécologues Obstétriciens de Langue Française de Belgique**

### **- Comité exécutif du GGOLFB**

- *J. Donnez (président)*
- *F. Van Den Brûle (secrétaire académique)*
- *V. Fonze (trésorier)*
- *M. Wayembergh (trésorier adjoint)*
- *S. Alexander*
- *R. Baumann*
- *J-M. Lacheron*
- *M. Marechal*
- *M. Masson*
- *R. Polet*
- *J. Squifflet*
- *J-C. Verougstraete*

### **- Groupe de travail Onco-GF**

- *M. Maréchal (directeur)*
- *M. Berlière*
- *M. Coibion*
- *F. Kridelka*
- *P. Simon*
- *J. Squifflet*
- *B. Vandermeersch*
- *T. Willems*
- *R. Bologne*
- *P. Cusumano*
- *M. Wayembergh*

